Anatomy of the Human Brain

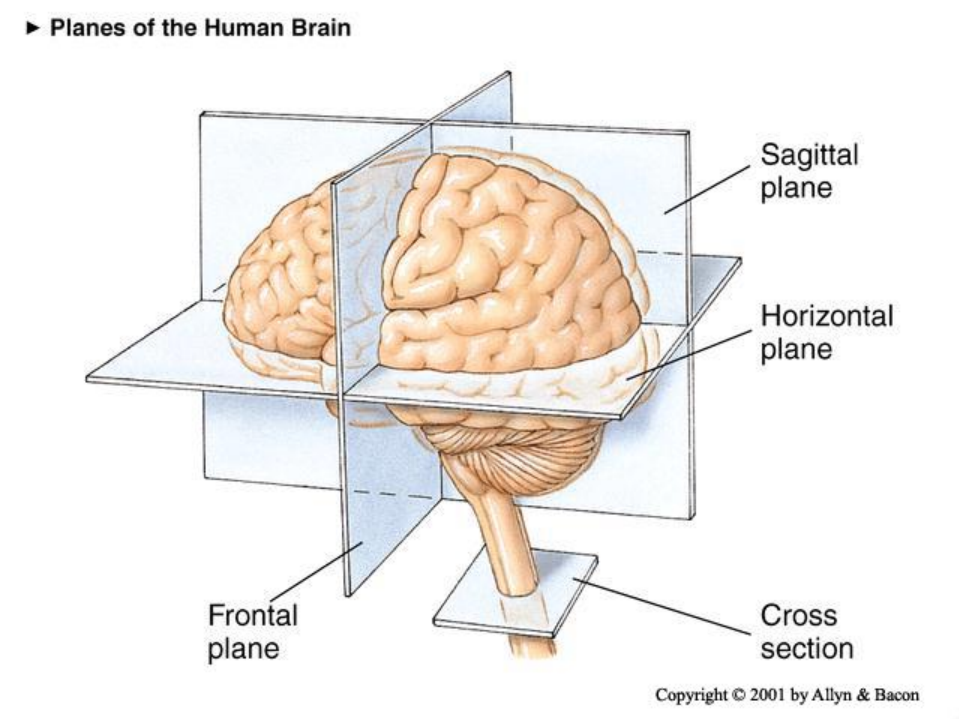

Overview



- Lobes of the brain (Forebrain)
- Midbrain/Hindbrain
- Protection and Blood supply
- Structure and Function of a neuron
- Synaptic Transmission
- Neurotransmitters

The brain

- Most complex organ of the body
- Contains billions of neural networks that interact to create human behaviour
- The brain is possibly the most complex organ to examine within the human body
- Although only weighing approximately 3lbs in the average adult, all behaviours, actions, thoughts and feelings originate from billions of neural networks interacting to create what we recognise as human.
- Without the brain our bodies simply would not function, making it important to have an understanding of its structure and function and the implications of diagnosis and pharmacology associated with mental illness.
- When looking at the brain, what is distinctive is the numerous folds that give it its wrinkled appearance. This folding together of brain tissue allows for greater amount of cerebral surface area (approx. two thirds of cerebral surface area is locate in the depths of these folds) to be confined within the limited space of the skull, leading to more information being relayed throughout areas of the brain
- The grooves are called fissures (extend deep into the brain) or sulci (if they are shallower) and the bumps that we see are called Gyri, and serve as markers to identify regions of the brain.

The Human Brain

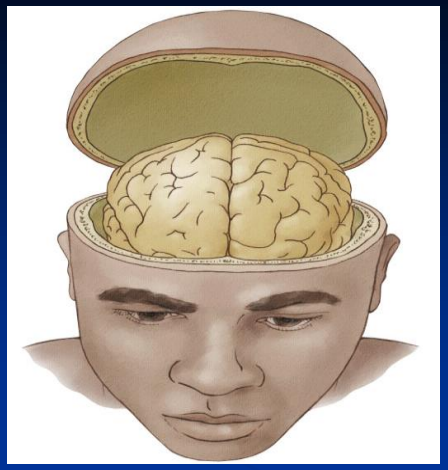

- The human brain is a gelatinous three-pound lump of connective tissue, spinal fluid and nerve cells.
- Its neurons generate some 25 watt of total power.
- It is in contact with every living cell in the body.
- It feels no pain!
- The human brain uses a pint-and-a-half of blood a minute.
- No matter what is happening to the body, the brain takes its nourishment first.
- For unknown reasons, the brain needs more blood when the body is asleep than when awake.
- One minute without oxygen or glucose results in unconsciousness
- 8 minutes without oxygen causes death

The Brain Has Three Main Anatomical Divisions:

- Forebrain (cerebrum)
- Midbrain
- Hindbrain (pons, medulla and cerebellum)

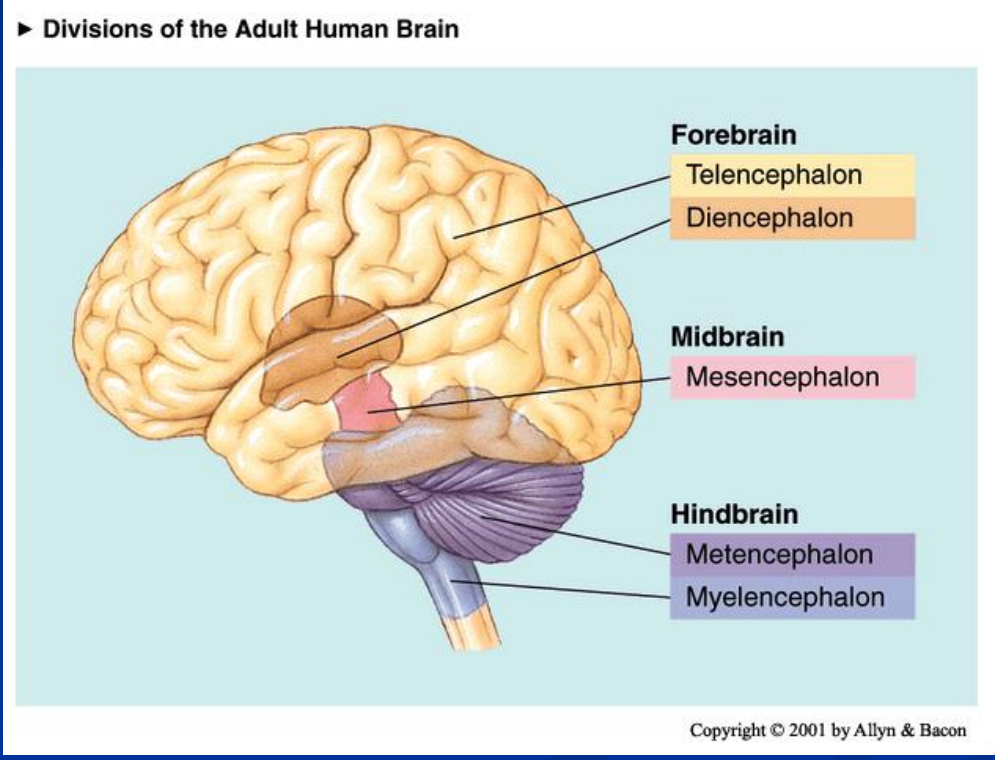

Three Functional Divisions:

Cerebrum

Sensory
and motor

Cerebellum

muscle coordination
and balance

Brainstem

vital regulations
heart, lungs, GI

The Brainstem

- Includes the midbrain
- The pons
- Medulla

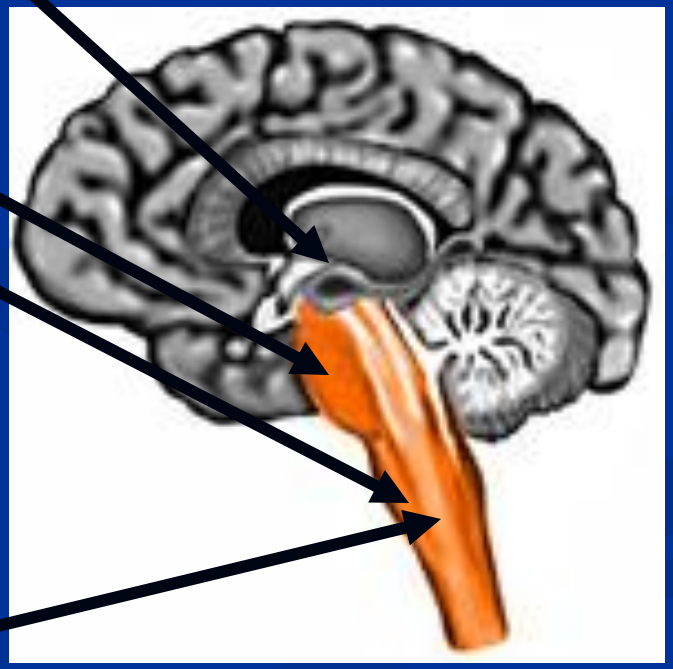

- Found in the brainstem is the Reticular Formation which regulates vital centers: heart, lungs, stomach, intestines and glands.
- Injury to the RF causes instant death.

The Cerebrum

- The cerebrum Is the largest part of the brain
- Weighs 2-2.5 lbs
- Contains the cortex
- Surface of cortex convolutions called gyri and infolds called sulci
  - Gyrus; Sulcus = Singular form
- Some sulci are pronounced and help form boundaries for the cerebral lobes
- Thalamus
- Hypothalamus

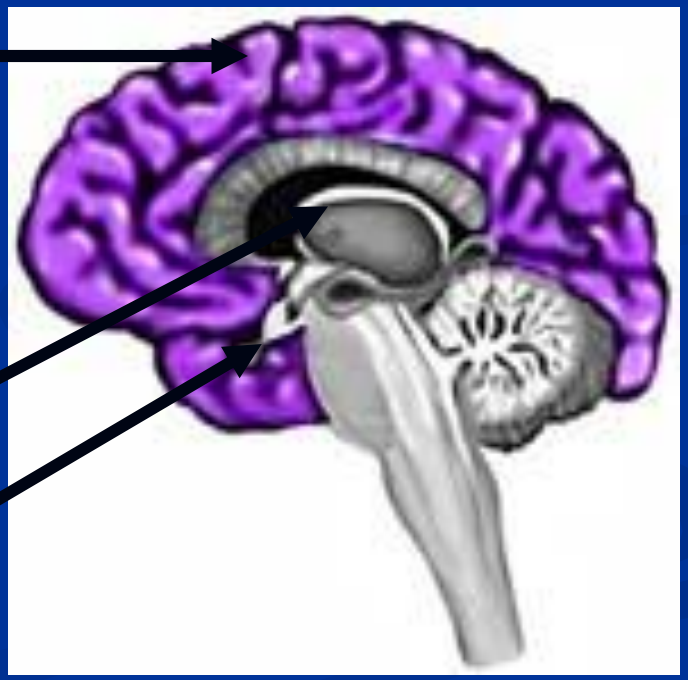

Gyri, sulci and lobes of the cerebrum

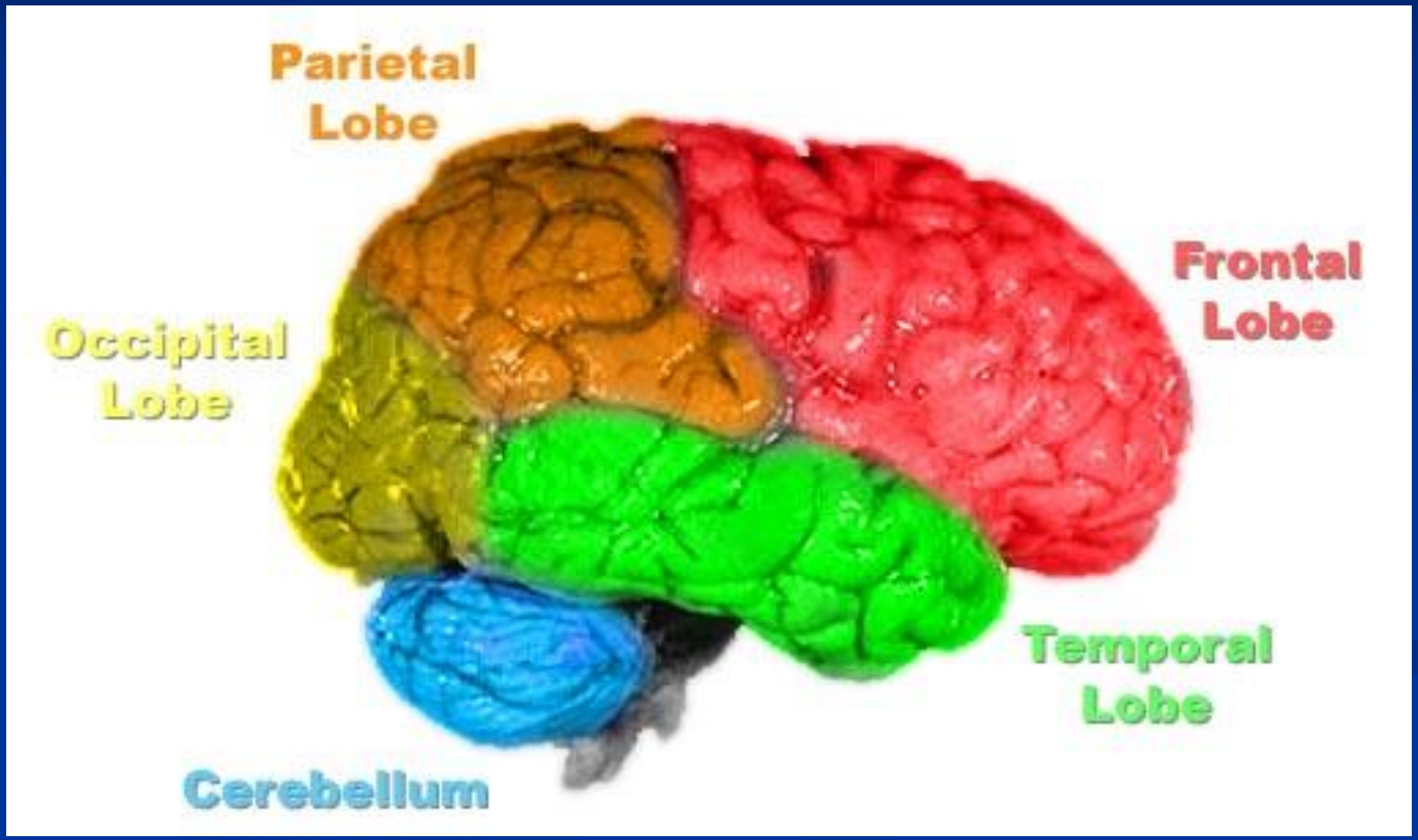

Forebrain

- Cerebrum and Cerebral cortex
- Left and Right Hemispheres
- Left hemisphere for most people is the dominant hemisphere- responsible for production of language, mathematical ability, problem solving, logic
- Right hemisphere thought to be responsible for creativity and spatial ability
- The cerebrum is the largest part of the brain and fills the entire upper portion of the cranium. It consists of the 2 cerebral hemispheres and sits atop of, and surrounds the brainstem leading to the spinal cord.
- Typically for most people the left hemisphere is dominant
- The cortex (the outer layer of the cerebrum) consists of 80% of the entire brain.

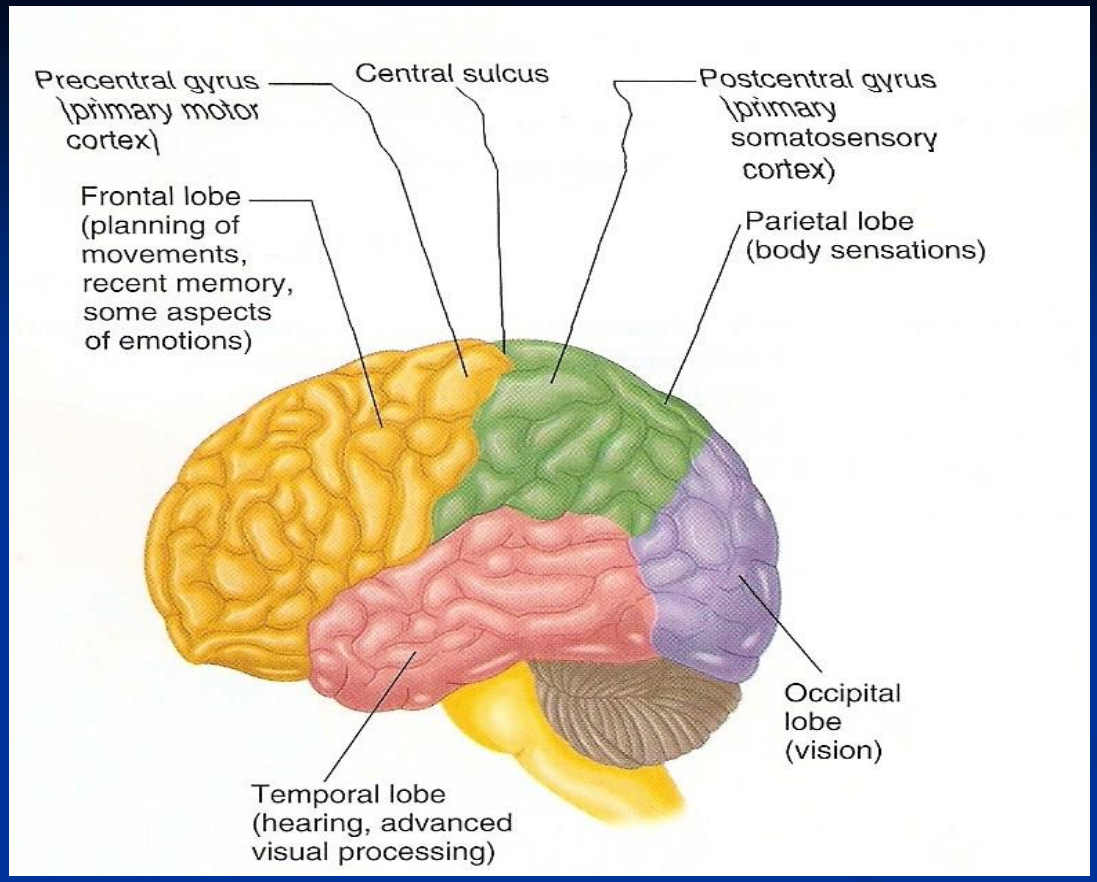

The major sections of the cerebral hemispheres are divided up in to sections or lobes. The lobes are named after the bones of the skull that overlie them.

Frontal Lobe

- Located in the front of both cerebral hemispheres, the frontal lobes are the largest lobes of the brain.
- Precise areas of the primary motor cortex represent particular areas of the body for example: the middle area of the cortex controls the legs, the lateral area is for the muscles of the face and largest area represented is for the arm and hands (located between both these areas).
- Posterior parietal cortex ,responsible for transforming visual information into motor commands
- -The pre-motor cortex ,responsible for motor guidance of movement and control of proximal and trunk muscles of the body.
- -The supplementary motor area (or SMA)- responsible for planning and coordination of complex movements such as those requiring two hands.
- The frontal lobes are also thought to be involved in complex functioning on the brain including personality, judgment, insight, reasoning, problem solving, abstract thinking and self evaluation termed executive functions. The frontal lobe also has a function in working memory especially the ability to plan and initiate activity.

The Cerebrum

- The cortex is an integrating area
- Brings together afferent (sensory) information
- Forms complex perceptual images
- Ultimate control over autonomic and somatic systems

The Cerebrum

- Thalamus contains part of the Reticular Formation
- Is a relay station for all incoming info. (except smell)
- Sends info to correct part of the cortex
- Concerned with emotions and motivation

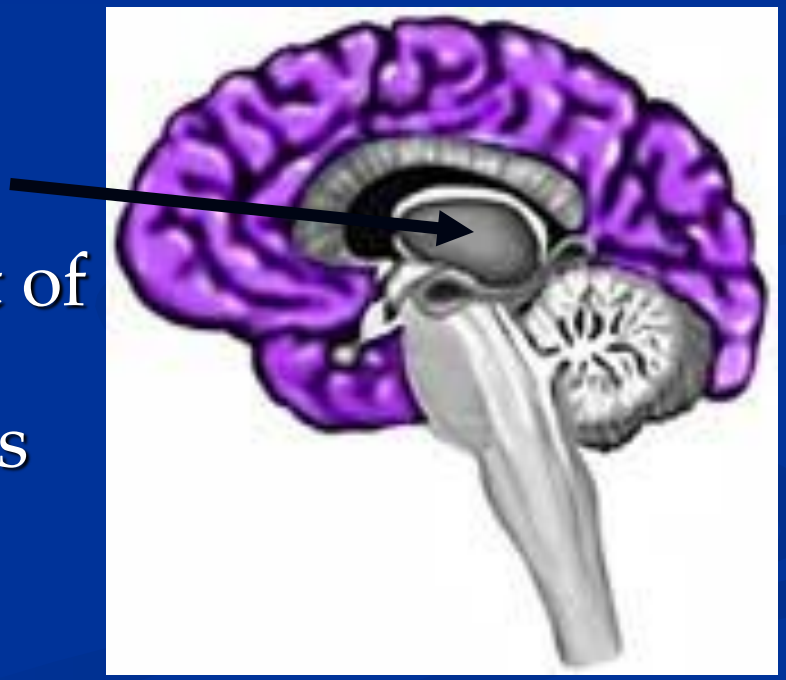

The Cerebrum

- Hypothalamus is also concerned with emotions and motivation
- Single most important regulation of internal environment (maintains homeostasis)
- Regulates temp, water balance, pituitary functions
- Food intake, gastric secretions

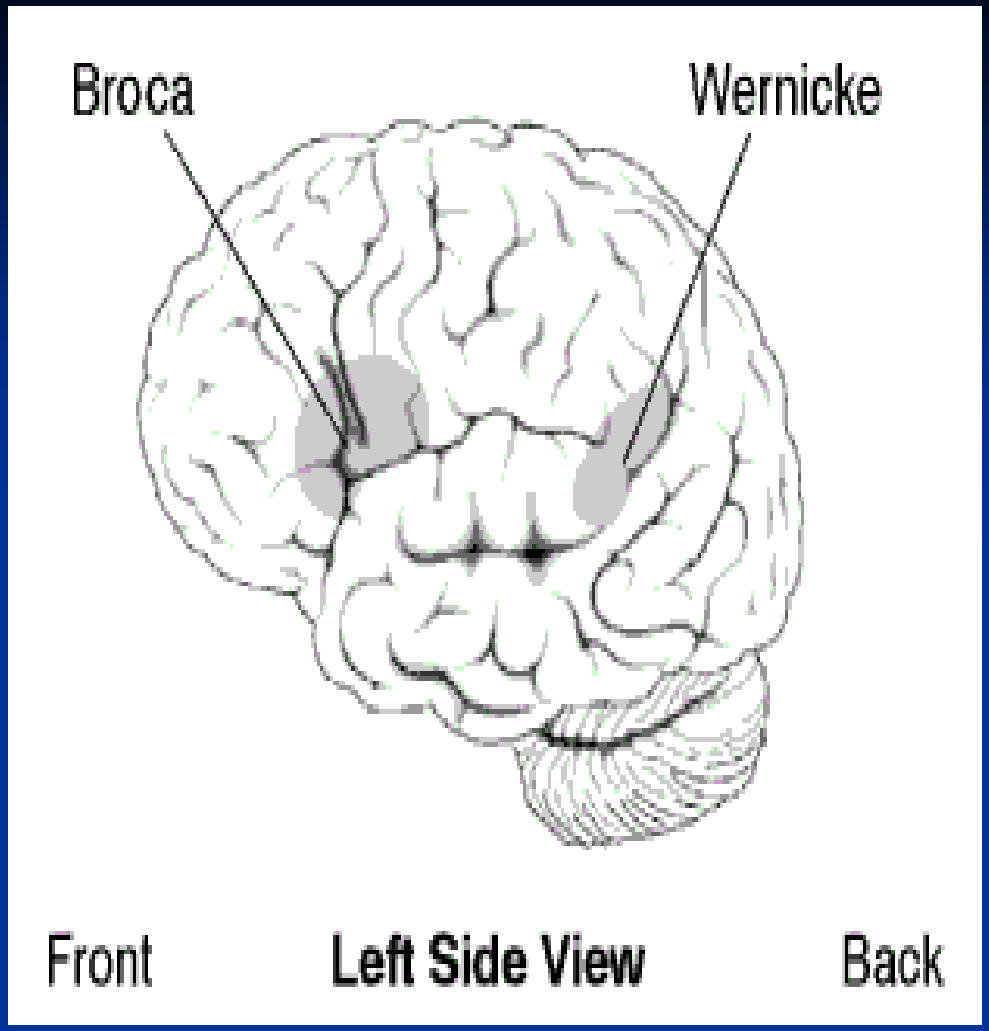

Broca's area is involved in the motor production of speech. Damage to this area produces expressive aphasia (difficulty producing the motor movements of speech

- Medulla oblongata- The medulla acts as a conduction pathway for ascending and descending nerve tracks for the conscious control of skeletal muscles, balance, co-ordination, regulating sound impulses in the inner ear, regulation of automatic responses such as heart rate, swallowing, vomiting, breathing, coughing and sneezing
- Reticular Formation- Important in arousal and maintaining consciousness, alertness attention and Reticular Activating System which controls all cyclic functions i.e. respiration, circadian rhythm.
- Damage to the RAS system can result in coma, and this is the main area of the brain anaesthetics suppress to put someone to sleep. Stimulating this area results in arousal.

Hindbrain

- Cerebellum- regulates equilibrium, muscle tone, postural control, fine movement and coordination of voluntary muscle movement.
- The cerebellum or 'little brain' is located posterior to the brain stem and plays and important role in sensory perception and fine motor control. The cerebellum has two main functions;
- 1) Receive input from all sensory sites and project this information to other parts of the brain such as the brainstem and thalamus.
- 2) Act as part of the motor system regulating equilibrium, muscle tone, postural control, and coordination of voluntary movement.
- cerebellum is the part of the brain which allows for fine movement. Damage to the area results in poor coordination, poor motor learning, and a loss of equilibrium

Hindbrain

- Pons- Relay station between cerebrum and cerebellum
- The pons is the main relay station between the cerebrum and the cerebellum.
- The majority of the brain's noradrenaline is produced in the locus cerculeus located within the pons and aids in regulating arousal and respiration.

Diencephalon

- Thalamus- filters sensory information, controls mood states and body movement associated with emotive states
- Hypothalamus- 'Central control' for pituitary gland. Regulates autonomic, emotional, endocrine and somatic function. Has a direct involvement in stress and mood states.
- All sensory pathways pass through the thalamus and are relayed to various areas throughout the brain. The thalamus accomplishes this by filtering incoming information and deciding what to pass on or not to pass on to cortex, preventing the overload of sensory information

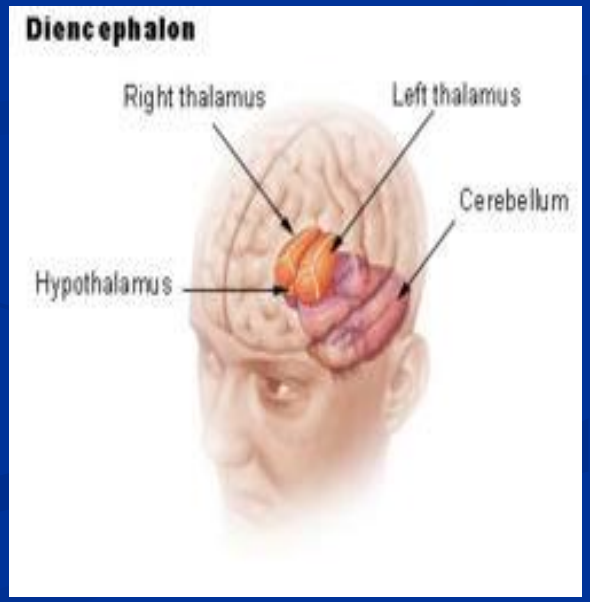

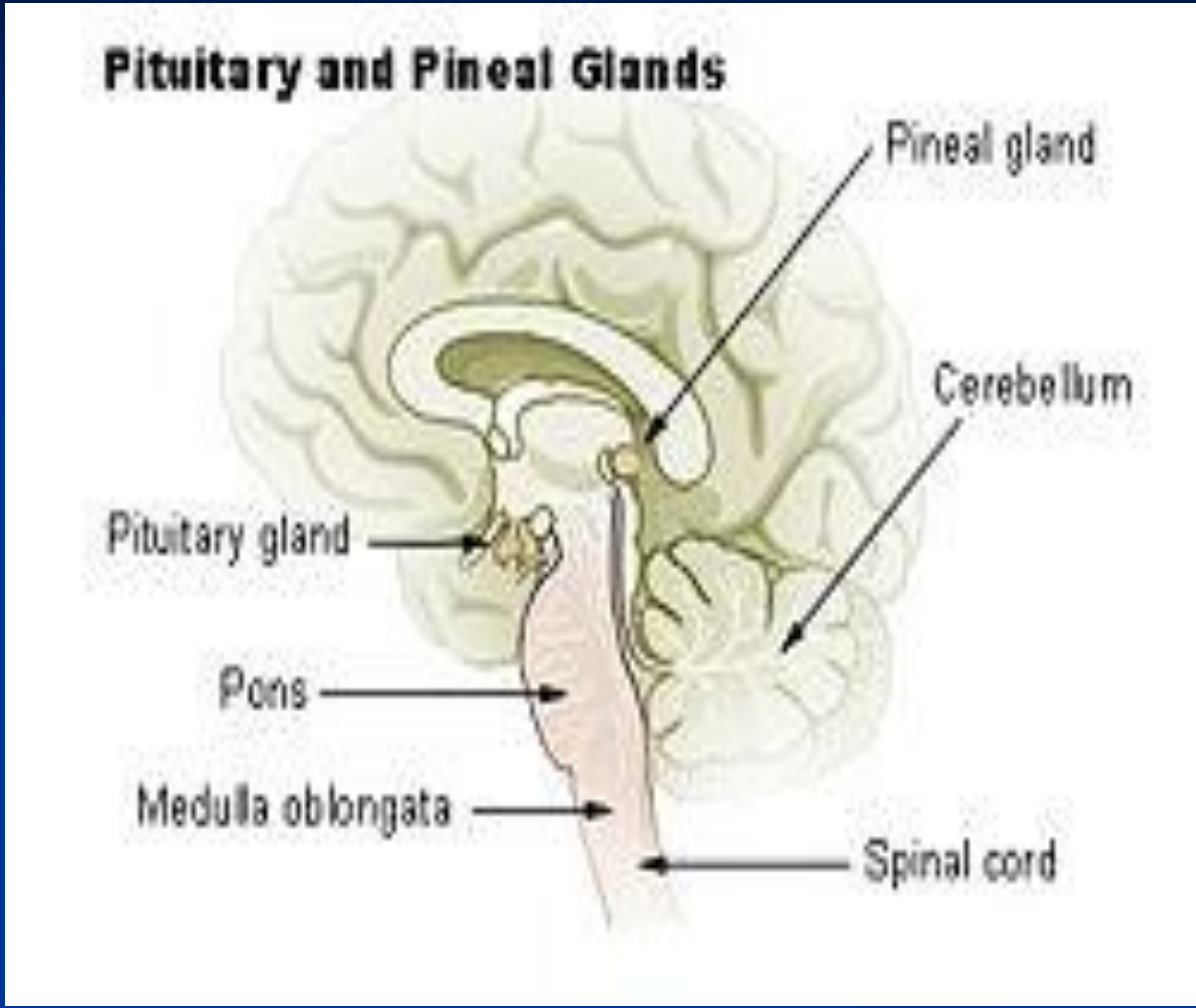
Pituitary and Pineal Glands
Pineal gland
Cerebellum
Pituitary gland
Pons
Medulla oblongata
Spinal cord

Pituitary gland (hypophysis) A small oval endocrine gland attached to the base of the vertebrate brain and consisting of an anterior and a posterior lobe, the secretions of which control the other endocrine glands and influence growth, metabolism, and maturation

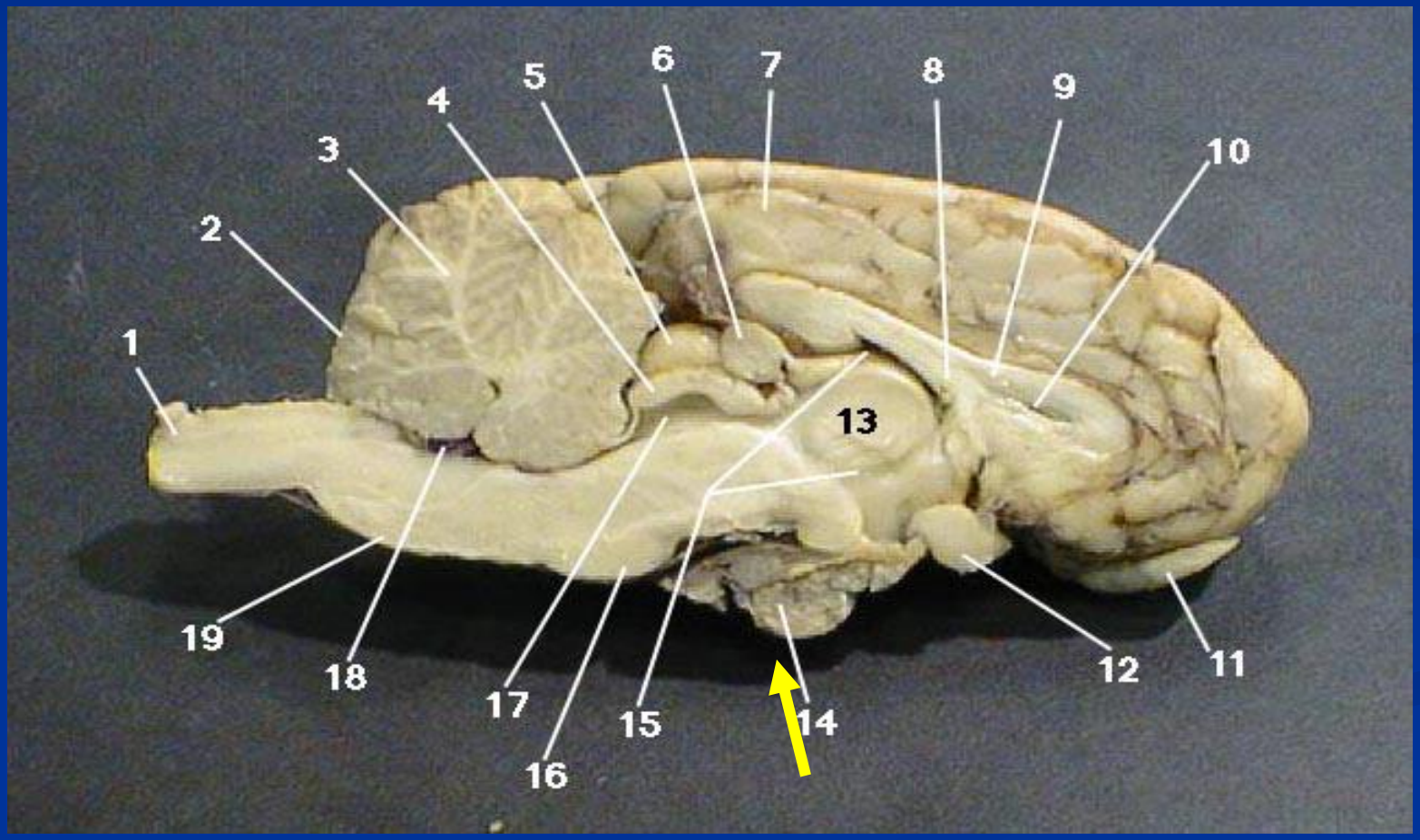

Pineal gland A small gland located deep within in the brain. It is believed to secrete melatonin, and may therefore be part of the body's sleep-regulation apparatus.

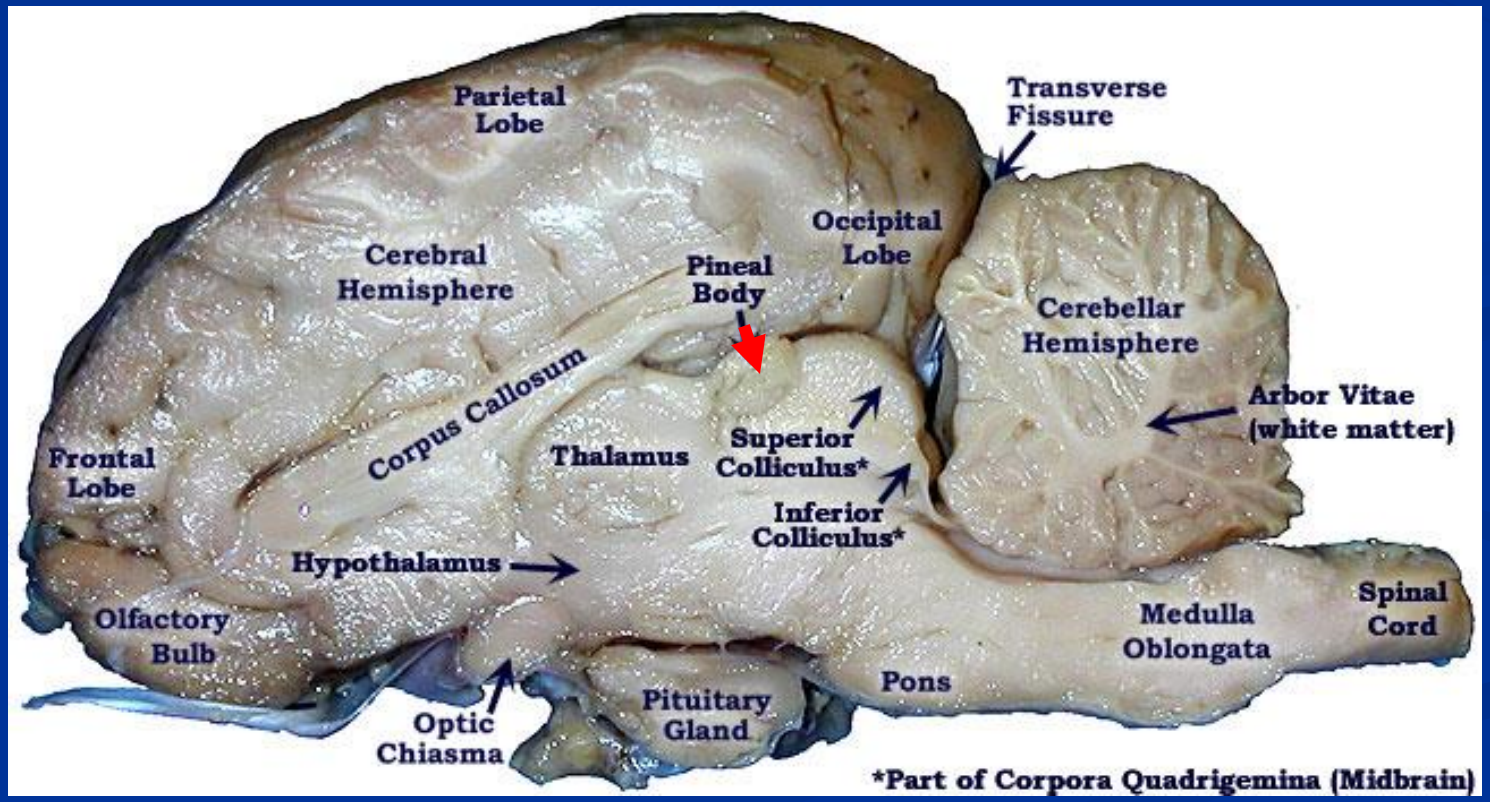

Corpus callosum structure in the mammalian brain that connects the left and right cerebral hemispheres. It is the largest white matter structure in the brain.

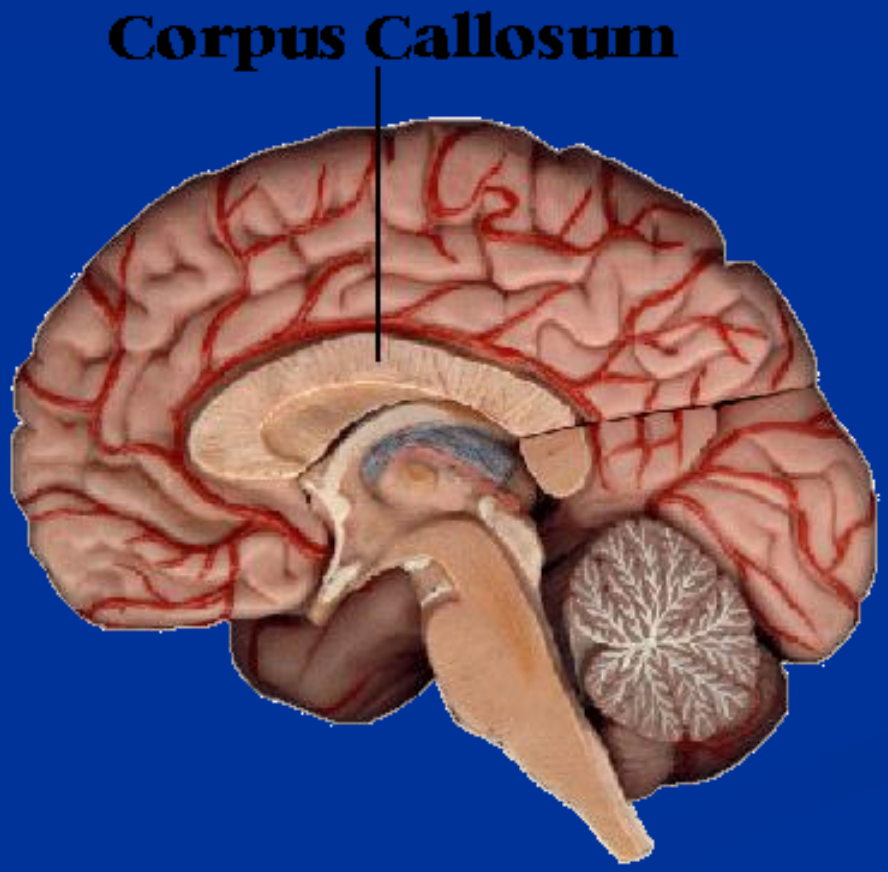

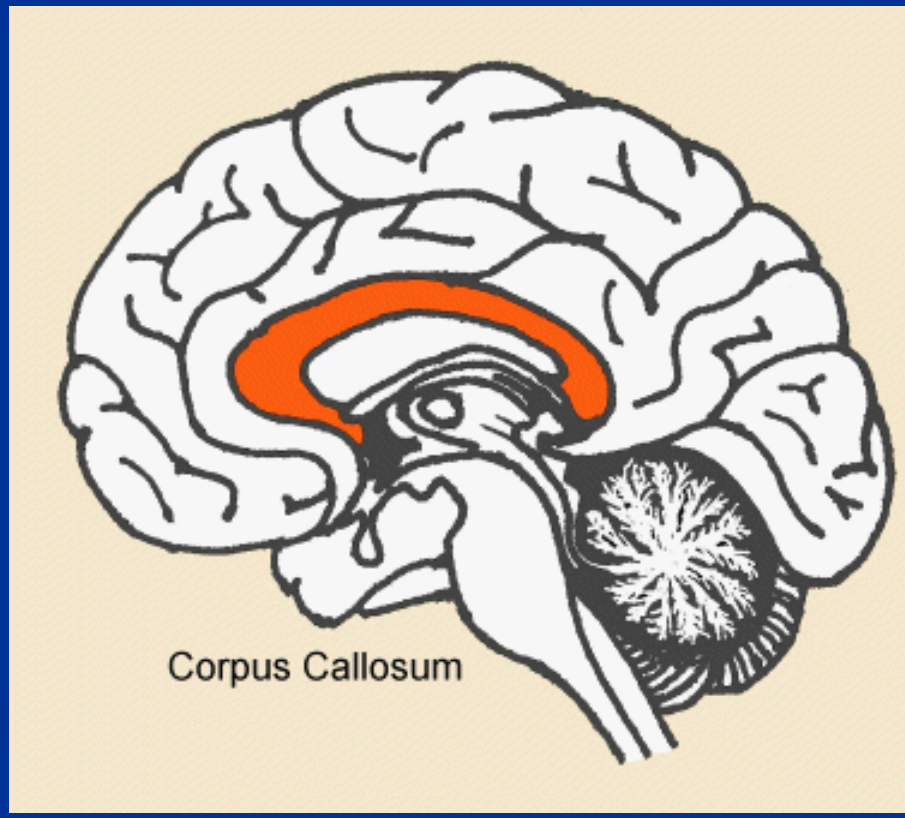

Corpus callosum

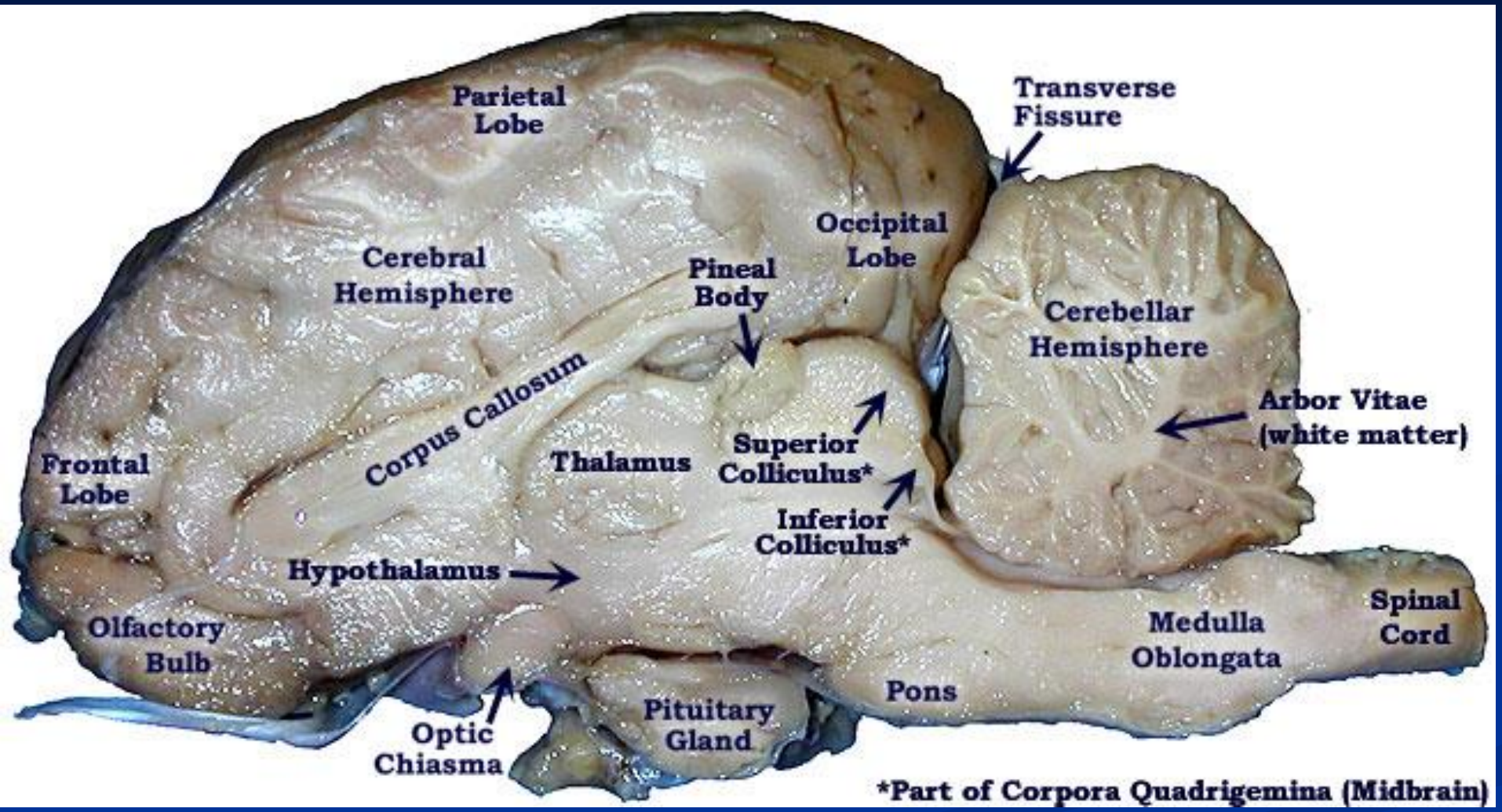

Temporal Lobes

- Located at each side of the brain
- Involved in receiving and processing auditory information , higher order visual information, complex aspects of memory and language
- are involved in receiving and processing auditory information, higher order visual information, complex aspects of memory, language and comprehension of language, abstract thought and judgement and control of written and verbal language skills
- Wernicke's Area- Comprehension of speech
- Wernicke's area is primarily responsible for comprehension of speech and closely linked with Broca's area to produce speech. Damage to this area is associated with reduced thiamine levels due to alcohol abuse :delirium.

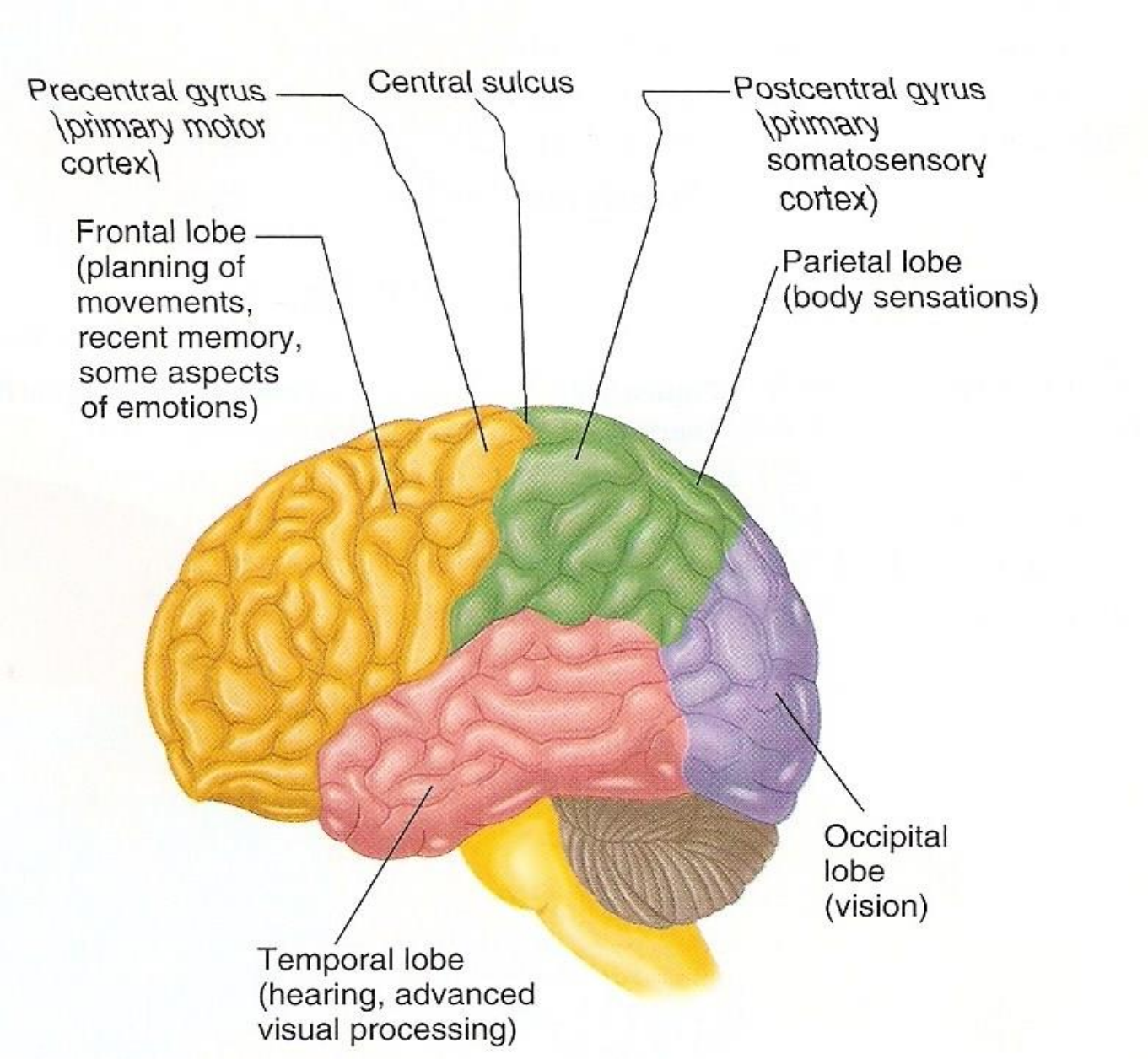

(Barlow and Durand , 2005)

Parietal lobe

- Located behind frontal lobe
- somato-sensory cortex (which receives general sensory information and initial reception of tactile (touch, pain, temperature) and proprioceptive(sense of position) information.
- The other main role of the parietal lobes are complex aspects of spatial orientation and perception, and the comprehension of language function and the ability to recognise objects by touch, calculate, write, recognise fingers of opposite hands and organise spatial directions.
- The posterior areas of the parietal lobes (through the dorsal stream of the visual cortex) appear to link visual and somatosensory information together.
- Damage to these areas produces the neglect of entire spaces of sensory information for example only eating from one side of a plate and other sensory deficits.

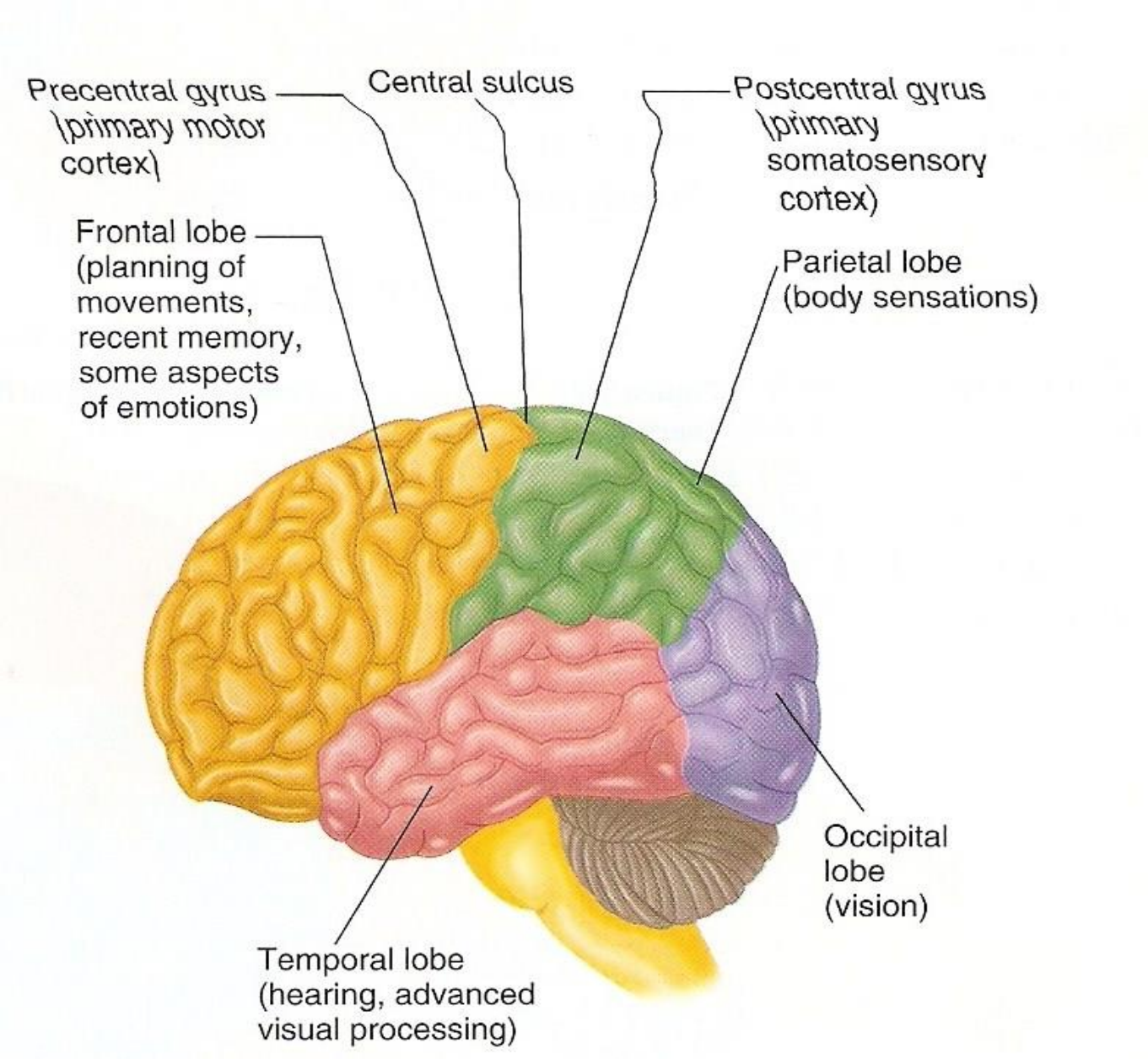
Precentral gyrus
\primary motor
cortex\
Central sulcus
Postcentral gyrus
\primary
somatosensory
cortex)
Frontal lobe
(planning of
movements,
recent memory,
some aspects
of emotions)
Parietal lobe
(body sensations)
Occipital
lobe
(vision)
Temporal lobe
(hearing, advanced
visual processing)

Occipital lobes

- Rearmost portion of the brain
- Visual processing area
- Corpus Callosum- Fibre bundle in the brain that connects the two hemispheres together.
- The primary visual cortex, which receives raw sensory information from the retina processes information on color, objects and facial recognition and is also involved in the perceiving motion.
- This allows for the transmission of information between the two hemispheres.
- Damage to the visual cortex causes cortical blindness (all structures to see are intact but the person cannot receive the input from the sensors).

Diencephalon

- The thalamus plays a role in mood and body movement associated with strong emotive responses such as fear or rage.
- some influence in prefrontal functions such as foresight and affect therefore its dysfunction has been implicated in abnormal behaviour.
- The hypothalamus can be viewed as the central control for the brain. It is located just below the thalamus, above the brain stem and is what keeps our body in homeostasis.
- It functions as the main control centre for the pituitary gland, regulating autonomic, emotional, endocrine and somatic function (body temperature, arterial blood pressure, thirst, fluid balance, gastric motility and secretions), plays a part in 'primitive' states directly involved in stress related and psychosomatic illnesses, controls emotional and mood relationships, physical drive such as hunger and sex and co-ordinates our sleep/wake cycle.

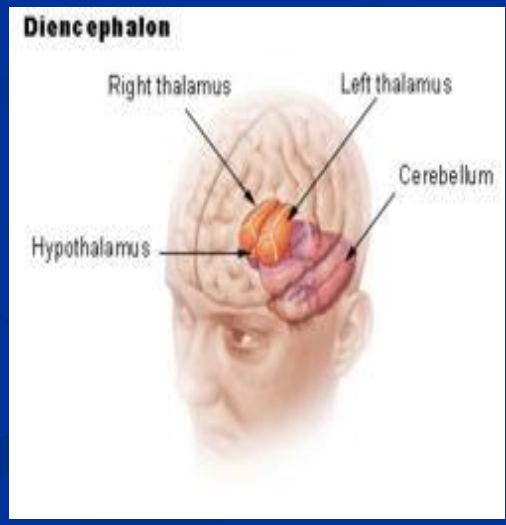

Gray Matter vs. White Matter

- **Gray matter**
  - Groups of neuron cell bodies and their dendrites
  - Composed of unmyelinated neurons
  - Distributed at the surface of the cerebrum & cerebellum, as well as in the depth of the cerebral, cerebellar, and spinal white matter
  - Function of gray matter is to route sensory or motor stimulus to interneurons of the CNS for creation of response to stimulus through chemical synapse activity.

Gray Matter vs. White Matter

- **White matter**
  - Composed of myelinated nerve cell processes, or axons, which connect various gray matter areas (the locations of nerve cell bodies) of the brain to each other and carry nerve impulses between neurons
  - Forms the bulk of the deep parts of the brain and the superficial parts of the spinal cord
- Generally, **white matter** can be understood as the parts of the brain and spinal cord responsible for information transmission (axons)
- Whereas, **gray matter** is mainly responsible for information processing (neuron bodies)

Gray and White Matter

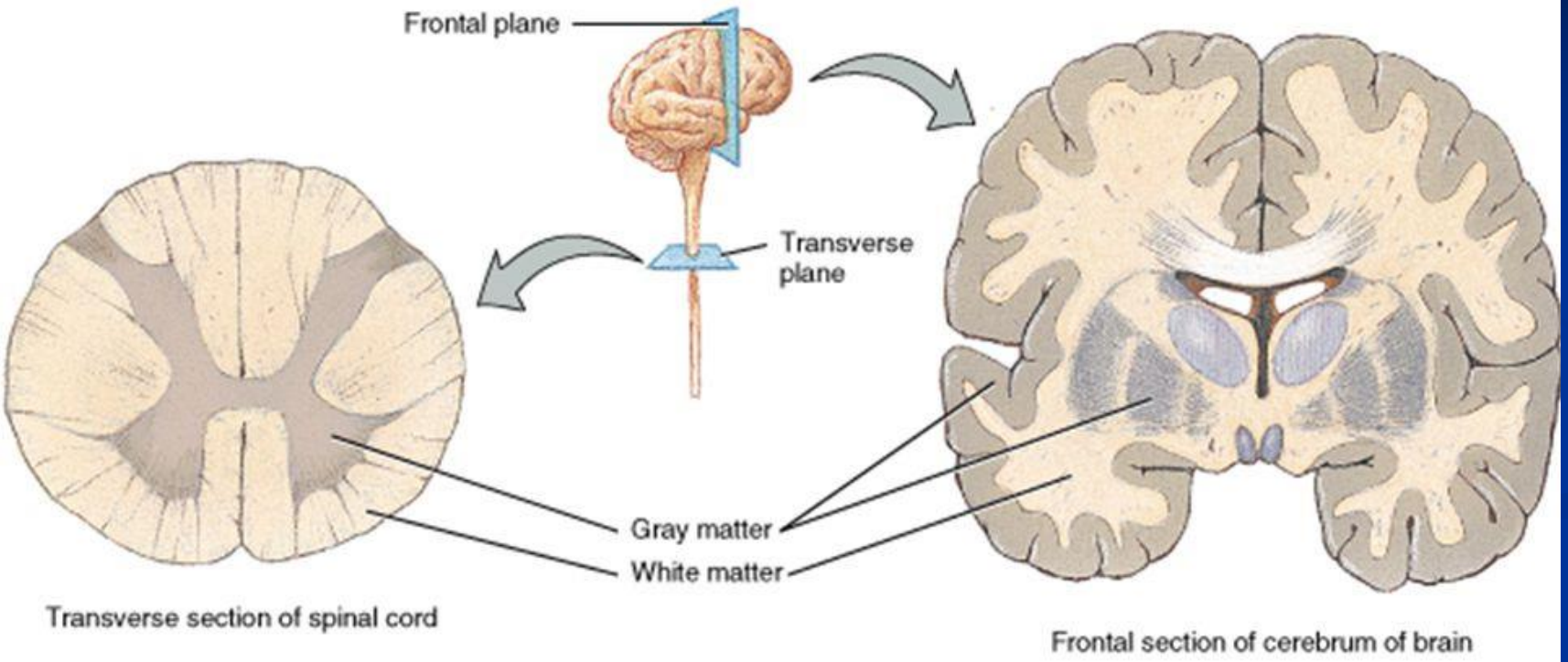

- White matter = myelinated nerve fibers
- Gray matter = nerve cell bodies, dendrites, neuroglia & unmyelinated axons

3 Membranes of CNS

- Dura mater
  - Consisting of the periosteal (attached to surface of the skull) and meningeal (<u>outer</u> covering of the brain) layers
- Arachnoid mater
  - Middle covering, attached to the inside of the dura, surrounds the brain and spinal cord but does not line the brain down into its sulci.
- Pia mater
  - Internal layer, clings to the surface of the brain.

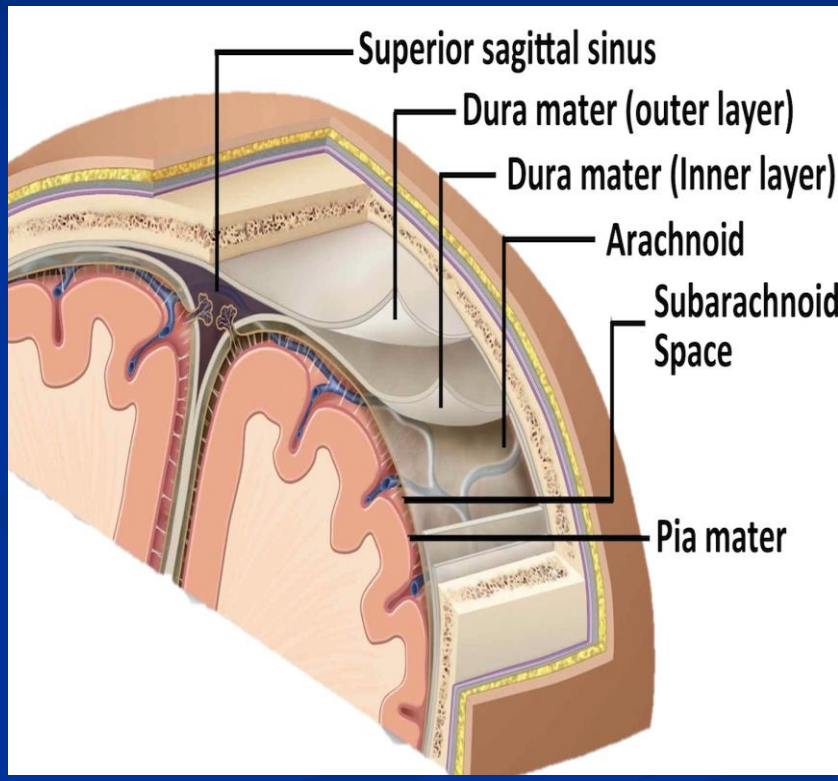

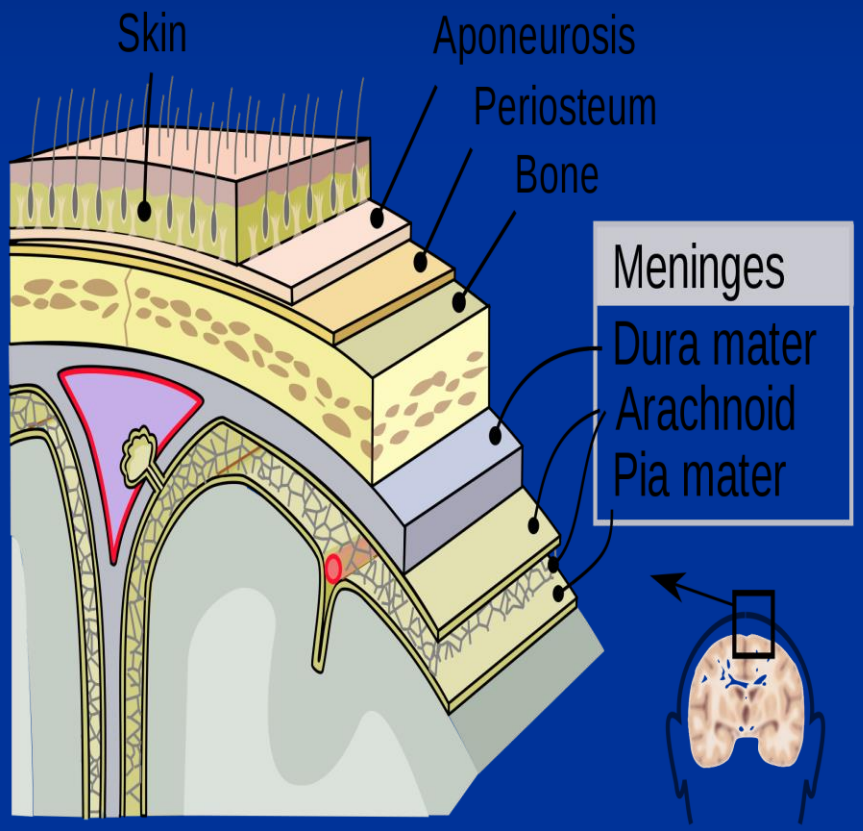
Skin
Aponeurosis
Periosteum
Bone
Meninges
Dura mater
Arachnoid
Pia mater

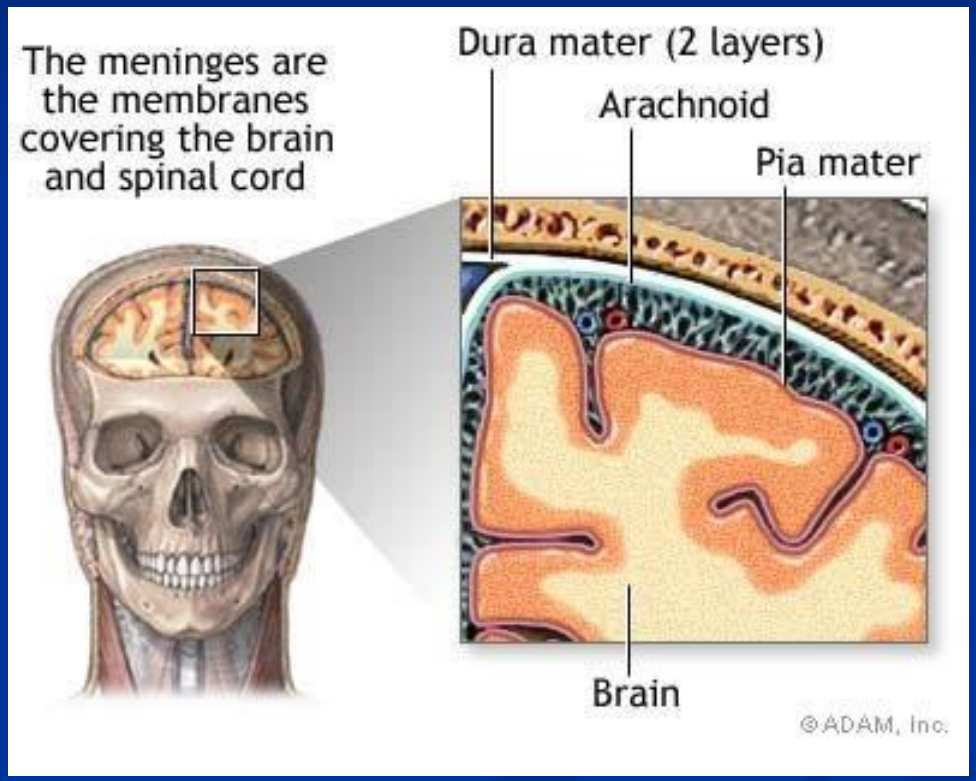
The meninges are the membranes covering the brain and spinal cord
Dura mater (2 layers)
Arachnoid
Pia mater
Brain
© ADAM, Inc.

Cerebrospinal Fluid

- Fills the brain ventricles, the central canal of the spinal cord, and the subarachnoid space.
- Bathes the brain & spinal cord, providing a protective cushion around the CNS.

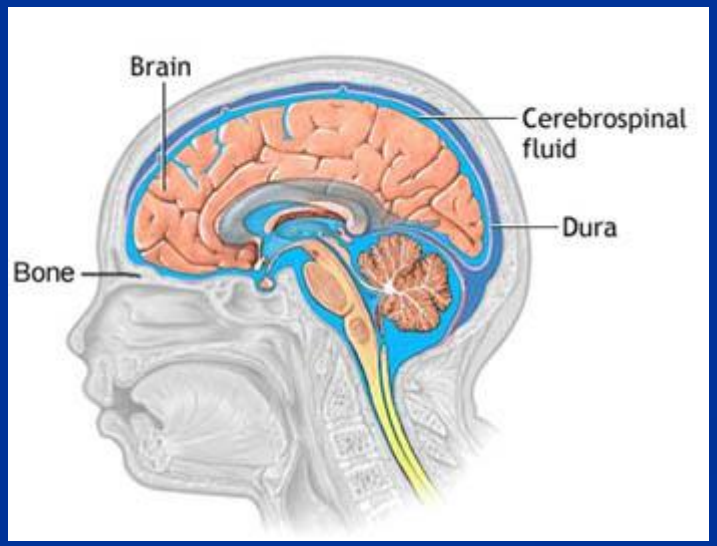

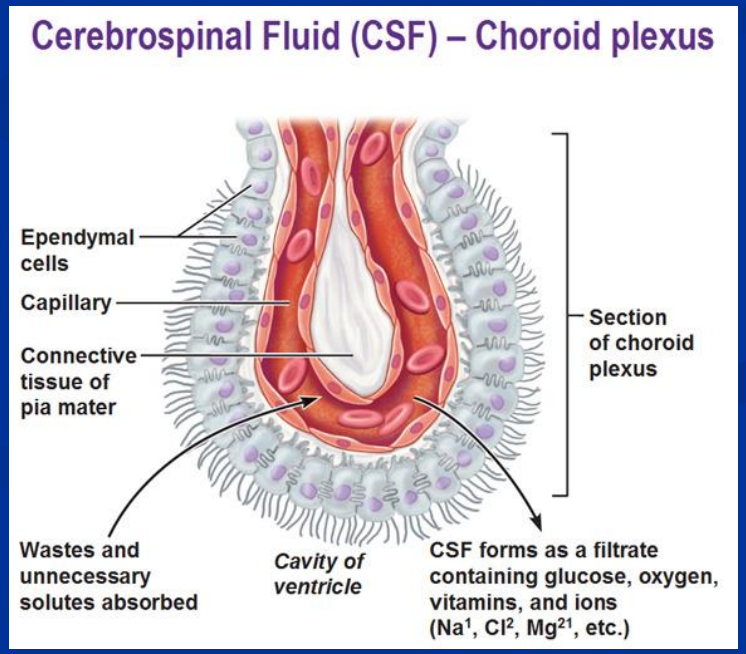

The Dura Mater and a Compressing Meningioma

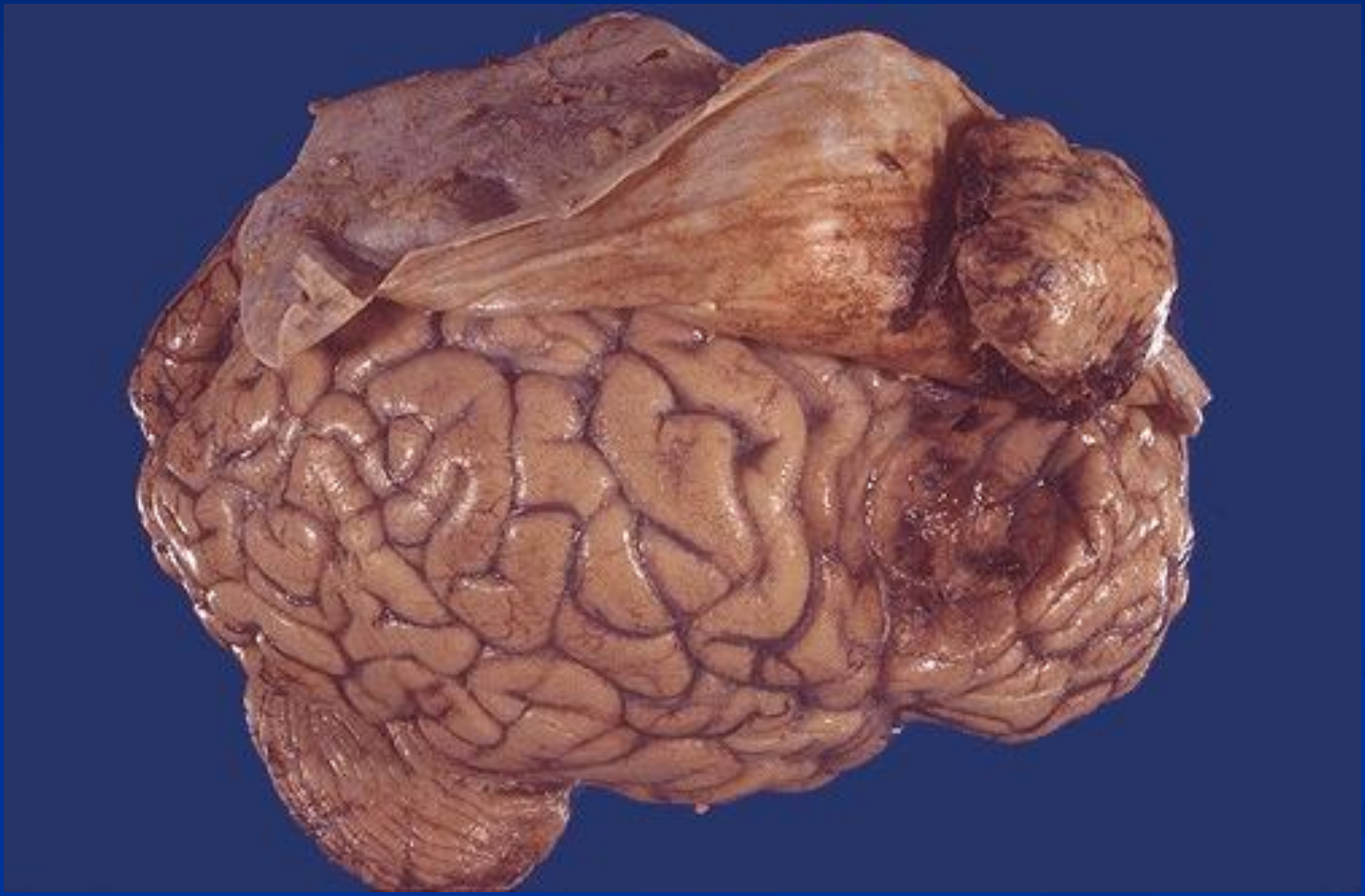

Pia Mater

Pia Mater